Biology 212: Anatomy and Physiology II
Lab #5: Anatomy of the Respiratory System

References: Saladin, KS: Anatomy and Physiology, The Unity of Form and Function 7th (2015)
Be sure you have read and understand Chapter 22 before beginning this lab.

INTRODUCTION:

Cells throughout the body require a continuous supply of oxygen (O_2) to support their metabolism, releasing carbon dioxide (CO_2) as a result. The primary role of the respiratory system is to supply the body with this oxygen and dispose of the carbon dioxide. For it to do this, four distinct processes must occur:

Pulmonary Ventilation: the movement of air in and out of the lungs, exchanging atmospheric air which is rich in O_2 but low in CO_2 with the air in our lungs which is rich in CO_2 but low in O_2. This requires that the air passages called bronchi and bronchioles, as well as the trachea and more proximal structures, remain open as pressures within them change.

Alveolar Gas Exchange: the movement of gasses between air and blood. This occurs in both directions between the air in alveoli of the lungs and the blood in capillaries surrounding those alveoli; oxygen diffuses from the air to the blood, while carbon dioxide diffuses from the blood to the air.

Transport of Respiratory Gases: blood (now high in oxygen and low in carbon dioxide after gas exchange has occurred) leaves the lungs through the pulmonary veins and carries this oxygen throughout the body. The blood returning to the lungs through the pulmonary arteries has given up its oxygen and picked up carbon dioxide.

Peripheral Gas Exchange: far away from the lungs, the oxygen picked up from the lungs diffuses out of the blood into the extracellular fluid surrounding cells in all parts of the body, while the metabolic waste product carbon dioxide diffuses into the blood to be returned to the lungs.

Only the first two of these processes, plus a small part of the third, occur within organs of the respiratory system. However, all four must occur correctly for the respiratory system to do its job, so the respiratory system and the circulatory system are intimately linked. Should either fail, cells will begin to die from the lack of oxygen and the buildup of carbon dioxide. If left uncorrected, this will soon cause death of the entire organism.

Be sure you understand these functions of the respiratory system before you begin this lab.

Learning Objectives

Upon completion of this exercise students will be able to:
- Identify the parts of the conducting portion and respiratory portion of the human respiratory system
- Describe the gross anatomy of the human nasal cavity and pharynx
- Describe the gross anatomy of the human larynx
- Describe the gross anatomy of the human trachea
- Describe the gross anatomy of the human lung
- Describe the histology of the human trachea
- Describe the histology of the human lung
- Describe the interface of air (in alveoli) and blood (in capillaries) at the respiratory membrane

GROSS ANATOMY OF THE RESPIRATORY SYSTEM:

The respiratory system is divided into two major parts based on both structural and functional criteria: The **conducting** portion of the respiratory system functions to condition and transport air between the external atmosphere and the lungs, and the **respiratory** portion of the respiratory system, is where gas exchange at the alveolar-capillary interface actually occurs

Exercise 1: Conducting Portion Anatomy

Part 1: On the torso model, identify the **nasal cavity** and observe how the **nasal septum** (only part may be shown), divides it into right and left halves. Identify the **superior**, **middle**, and **inferior nasal conchae** which project medially from the lateral walls. Identify the **hard palate** and **soft palate** which separate the nasal cavity from the **oral cavity**. Observe that the tongue occupies most of this cavity.

Although not well shown on the model, you should realize that both the nasal cavity and oral cavity open posteriorly into the **pharynx**. In its superior part, identify the opening of the **auditory** or **Eustachian tube**.

In the neck of the model, identify where the **larynx** branches away from the pharynx, leading into the **trachea.** Follow the trahea into the thorax. You can see and feel the **rings of hyaline cartilage** which surround it. Although not shown on this model, you should realize (Figure 22.7 in your Saladin text) that these rings are incomplete posteriorly. Observe that in the neck, the trachea is anterior to the esophagus, and the major vessels of the neck (common carotid arteries and internal jugular veins) are lateral to it. The thyroid gland bridges over its anterior surface. As it enters the thorax, the trachea remains anterior to the esophagus but passes posterior to the arch of the aorta and its branches (the brachiocephalic, left common carotid, and left subclavian arteries).

Shortly after entering the thorax, the trachea divides into **right and left primary bronchi** (singular = **bronchus**) which carry air into and out of their respective lungs. Notice that these are relatively short and enter the lungs just a short distance after this division. The hyaline cartilage rings continue onto the bronchi and will, in fact, continue to surround air passages well into the substance of the lung.

Questions for discussion:

You can breathe through either your mouth or your nose. Explain the anatomical basis for this.

How does the larynx allow air to pass from the pharynx into the trachea but prevent food or liquids from doing so? (Hint: Feel how your larynx moves when you swallow)

What is the physiologic importance of these cartilage rings which surround the trachea and bronchi?

Each breath you inhale contains millions of foreign particles: bacteria, viruses, pollen, dust, smoke particles, etc. It all of these reached the alveoli of your lung you would quickly die. How do your nasal cavity, trachea and bronchi trap and dispose of these particles to prevent them from reaching the alveoli?

<u>Part 2:</u> Examine Figures 22.7 and 22.9 in your Saladin text and identify **the primary (main) bronchi**, **secondary (lobar) bronchi**, and **tertiary (segmental) bronchi** within each lung. These bronchi repeatedly branch and divide, becoming smaller and smaller as they lead toward the respiratory regions of the lungs. As discussed in your Saladin text, these eventually form microscopic structures called **terminal bronchioles**, so named because they are at the end ('terminus") of the conduction portion of the lung. Terminal bronchioles are shown in Figure 22.12 of your Saladin text.

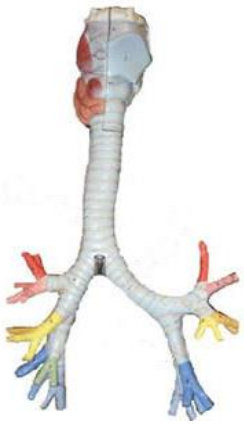

Examine the model of the larynx, trachea, and bronchi . Identify

- two primary bronchi. Each primary bronchus leads to one **lung**
- three secondary bronchi in the right lung and two secondary bronchi in the left lung. Each secondary bronchus leads to one **lobe** of a lung.
- ten tertiary bronchi in the right lung and eight or nine tertiary bronchi in the left lung, each one color-coded and numbered from "1" to "10". Each tertiary bronchus leads to one of the **bronchopulmonary segments** which the lobes are divided into..

Each lung, each lobe of a lung, and each bronchopulmonary segment can function independently because it is supplied by just one bronchus and one branch of the pulmonary artery. Thus, it can be easily isolated in the case of infection or cancer without affecting the rest of the lungs.

Exercise #2: Respiratory Anatomy Leading to Alveoli for Gas Exchange

After inhaled air passes through the terminal bronchioles it enters the respiratory portion of the lung, so named because it is now possible for **gas exchange** of oxygen and carbon dioxide to occur. Terminal bronchioles divide to form **respiratory bronchioles, alveolar ducts,** and eventually **alveoli** (singular = **alveolus**). While a minimal amount of actual gas exchange occurs in the respiratory bronchioles and alveolar ducts, the alveoli are the primary areas for gas exchange. Note on Figure 22.12 of your Saladin text how each alveolus is wrapped by a network of capillaries. These, of course, are part of the pulmonary circuit of the circulatory system, and they contain the blood with which oxygen and carbon dioxide will be exchanged with the air in the alveoli.

As shown in Figure 22.12b of your Saladin text, within each alveolus there are three types of cells **type 1 alveolar epithelial cells** which participate in gas exchange**, type 2 alveolar cells** which produce pulmonary surfactant, and **alveolar macrophages** which are phagocytic and clear debris and pathogens from the alveoli. Be sure you can identify each of these types of cells on Figure 22.12b.

Question for discussion:

Describe to your lab partners what would happen to you if each one of these three types of cells was unable to carry out its normal function.

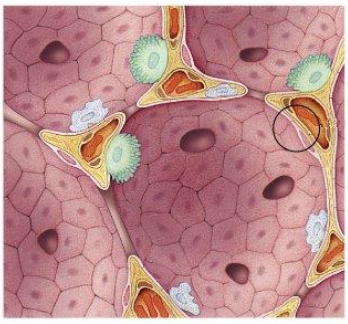

A key adaptation that allows the lung alveolus to exchange gases so efficiently is the extremely thin structure of the **respiratory membrane**. This is not a classic cell membrane, but rather it is formed by three structures which lie next to each other:

- the simple squamous epithelium of the alveolus formed by the type 1 alveolar cells,
- the simple squamous epithelium forming the endothelium of the capillaries
- a very thin basement membrane between these two layers of epithelium

For oxygen to pass from the alveolus into the blood, it must pass through the alveolar epithelial cell, diffuse through the basement membrane and then pass through the endothelial cells that line the blood capillaries. It can then enter the erythrocytes and bind onto the hemoglobin which they contain.

Be sure you can identify the parts of the respiratory membrane of Figure 22.12c.

Question for discussion:

Describe to your lab partners what would happen to you if the respiratory membranes of your alveoli swelled and thickened because of pulmonary edema (accumulation of fluid in the lungs).

Exercise #3: Gross Anatomy of the Lung

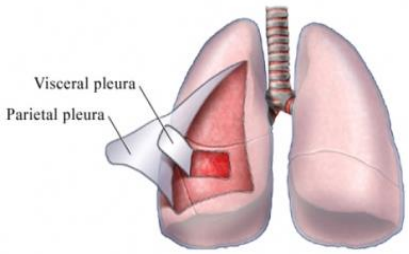

Part 1: On Figures A-6, 22.1 and 22.10 of your Saladin text, notice how the lungs are situated in the lateral parts of the thoracic cavity and are surrounded by a double-layered serous membrane called the **pleura**. One layer is attached to the lung and is referred to as the **visceral pleura**, while the other layer lines the thoracic cavity and is known as the **parietal pleura**. Between these two layers is a potential space known as the **pleural cavity**, which contains a thin, slippery fluid known as pleural fluid. This allow the lungs to move within the pleura cavities with very little friction as you breathe. The parietal pleura is attached to the fibrous pericardium medially, the diaphragm inferiorly, and the ribs anteriorly, laterally, and posteriorly.

You may remember that the heart is not situated perfectly centered within the thorax. Rather, the heart tends to be slightly angled towards the left half of the body and as a result occupies more space on the left side of the thorax than the right. To accommodate this, the left lung is slightly smaller than the right lung in order to accommodate the positioning of the heart.

Using the torso models and Figure 22.9 in your Saladin textbook, notice that deep fissures divide the right lung into three lobes and the left lung into two lobes.

What are these **lobes** called? Right lung - 1.

2.

3.

Left lung - 1.

2.

What are these **fissures** called? Right lung - 1.

2.

Left lung - 1.

On the right lung the _____ fissure separates the _____ and _____ lobes

and the _____ fissure separates the _____ and _____ lobes

On the left lung the _____ fissure separates the _____ and _____ lobes

Identify the **hilum** on the mediastinal surface of each lung where the primary bronchus, pulmonary artery, and pulmonary veins enter it. The rest of the lung is free to move during respiration. Although not well shown on the torso models, you should understand how each lung is surrounded by visceral and parietal layers of the pleura, with the pleural cavity between them.

Part 2: Each lung exhibits several surfaces which are named for the structures they face. Using Figure 22.9 in your Saladin text, identify the **diaphragmatic** surface facing the diaphragm, the **costal** surface facing the rib cage, and the **mediastinal** surface facing the heart and trachea. Identify the **apex** of each lung, which actually extends upward out of the thoracic cavity and into the neck

Part 3: Wearing gloves, examine the preserved human lungs and, if available, fresh sheep or cow heart-lung combinations. On each human lung, identify:

Superior, middle (right lung only), and **inferior lobes**

Horizontal (right lung only) and **oblique fissures**

Costal, mediastinal, and **diaphragmatic surfaces**

Hilum

Cardiac impression (left lung only)

Notice that some of the openings at the hilum have **cartilage** in their walls, so they must be **bronchi**. The other openings at the hilum are the **pulmonary arteries** and **pulmonary veins**, although it will be difficult to differentiate between these. In general, the arteries will have thicker walls than the veins, but don't waste much time on this.

On the fresh heart-lung combinations of a sheep or cow, if available, observe how the primary bronchi, pulmonary arteries, and pulmonary veins enter the hilum of each lung. Note how the surface of each lung feels very light and soft because of the air-filled alveoli. Observe how fissures divide each lung into lobes, but the lungs of cattle and pigs have different numbers of lobes than do humans so do not try to name the lobes or fissures in these specimens.

Insert a syringe or squeeze bottle into different primary or secondary bronchi of these fresh specimens and observe how each bronchi inflates a very specific segment of the lung. Do not worry about damaging the lung, go ahead and stretch-pull-inflate as hard as you like. How does elasticity in the lung tissue contribute to passive exhalation when the syringe used for inflation is removed.

Exercise 4: Examine the large model of the cartilages of the **larynx**. Obviously, this does not include the soft tissues such as muscles, membranes, or ligaments which are also part of this organ. It also does not show the smallest pair of cartilages called the cuneiform cartilages.

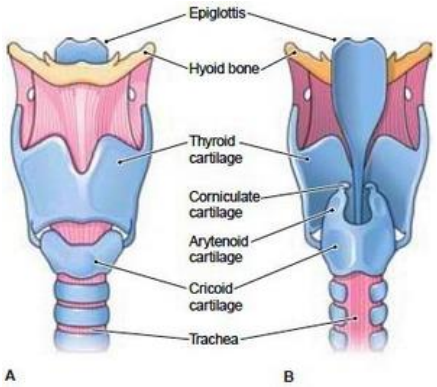

As shown in Figure 22.4 of your Saladin text, the larynx consists of nine cartilages: three large single ones; and six smaller cartilages arranged as three pairs. Identify the **thyroid cartilage**, which is the largest cartilage of the larynx. It has a “V” shape with the point facing anteriorly and the open part facing posteriorly. Projections on either side, called **cornu** (“horns”) extend superiorly to articulate with the **hyoid bone**. Just inferior to the thyroid cartilage is the **cricoid cartilage**, the only one which completely surrounds the larynx. Notice that it is much larger anteriorly than it is posteriorly. The third large single cartilage is the **epiglottis**, whose narrow inferior end is attached inferiorly to the thyroid cartilage, leaving its wider superior end is free to move. Look on the posterior surface of the model and identify the **arytenoid cartilages** on either side. The **corniculate cartilages**, which in life are individual, are shown on this model as superior and posterior extensions of the arytenoid cartilages. The pair of **cuneiform cartilages** are not shown on this model, but are situated just superior to the corniculate cartilages.

Exercise 5: Examine the smaller larynx model and identify the location of each cartilage listed in Exercise 4 even if it is covered with soft tissues. Notice two ridges of tissue extending from anterior to posterior on either side of the larynx. The inferior ridges are the **vocal folds**, also called **vocal cords** or **vocal ligaments**. The slit-like opening between the right and left vocal folds is the **glottis**. The more superior folds of the mucosa are the **vestibular folds**, also called the **false vocal cords**.

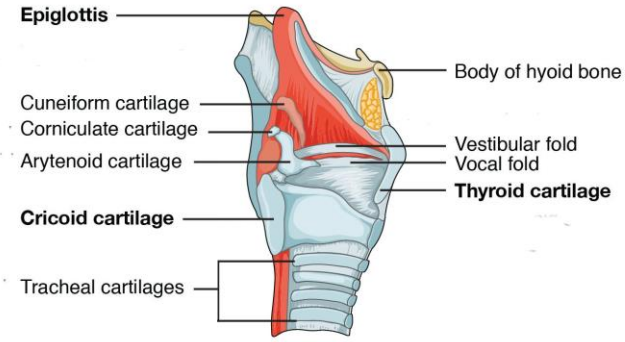

Inferior to the cricoid cartilage of the larynx is a portion of the trachea. This model clearly shows that the cartilage rings, which support the wall of the trachea, are "C"-shaped with the opening directed posteriorly.

Go back to the large model showing the cartilages of the larynx and notice that the arytenoid cartilage on each side has an anterior-facing projection. This is where the vocal fold on that side attaches posteriorly. The anterior end of each vocal fold attaches to the thyroid cartilage. Some of the models will have these folds in place, but you should understand their location and attachments even if missing on the model.

Question for discussion:

After examining Figure 22.6 and reading the accompanying text in Saladin, explain to other members of your lab group how the vocal cords are abducted and adducted by movement of the arytenoid cartilages and how their tension can be increased or decreased during vocalization and breathing.

List in the proper order all of the structures through air passes as you inhale, from the nasal cavity to the alveoli. Be sure to identify which of these are part of the conduction portion of the respiratory system and which of them are part of the respiratory portion.

HISTOLOGY OF THE RESPIRATORY SYSTEM:

Parts of the pharynx are also part of the digestive system and carry both food and drink as well as air so they need to withstand a certain amount of abrasion and are thus lined by a **non-keratinized, stratified squamous epithelium**. Most of the rest of the conducting portion of the respiratory system is lined by a **pseudostratified columnar epithelium** with **cilia** extending from the surface of the cells. Some of these cells, called **goblet cells** because of their appearance under the light microscope, secrete mucous onto the surface of the epithelium and many larger **mucous glands** located just deep to the epithelium secrete their contents onto this surface. This sticky layer of mucous traps dust, bacteria, mold spores, and many other things in the air before they can reach the alveoli, and the cilia work in unison to sweep it toward the pharynx where you can swallow it. Since the vocal folds of the larynx are instead lined with a stratified squamous epithelium to withstand the abrasion between them, this layer of mucous and cilia is discontinuous at that point, which is why you have to cough or clear your throat to get the mucous from your trachea into the pharynx.

As the bronchi and bronchioles divide into smaller and smaller passages the amount of cartilage decreases, and the shape of the epithelial cells gradually transitions from pseudostratified columnar to cuboidal (respiratory bronchioles) to simple squamous (within the alveoli).

Exercise 6: Slide #7 is a slide of the trachea. Examine this under low power to identify its **epithelium** and the deeper **hyaline cartilage** surrounded by **loose connective tissue**. You may also see **smooth muscle** extending from the ends of the cartilage rings. Switch to higher magnifications and confirm that the epithelium is indeed a **pseudostratified columnar epithelium** (Figure 22.7). The **cilia** will appear as a fuzzy layer on the inner surface. You should also be able to identify **goblet cells** within the epithelium.

Question for discussion:

Explain the function of those cilia to other members of your lab group. What would happen if the cilia were not able to carry out that function?

Explain the function of the cartilage rig of the trachea to other members of your lab group. Based on your reading of Chapter 22 before this lab exercise and your understanding of how difference in pressure produce respiration (Figure 22.16), explain what would happen if those cartilage rings were not present.

Exercise 7: Examine slide #2, which is a section of the lung. Identify the thin **alveolar walls** surrounding and separating the empty **alveoli**. The cells which line these alveoli are so flat that, even under the highest power magnification on your microscopes, you are unlikely to see any cytoplasm.

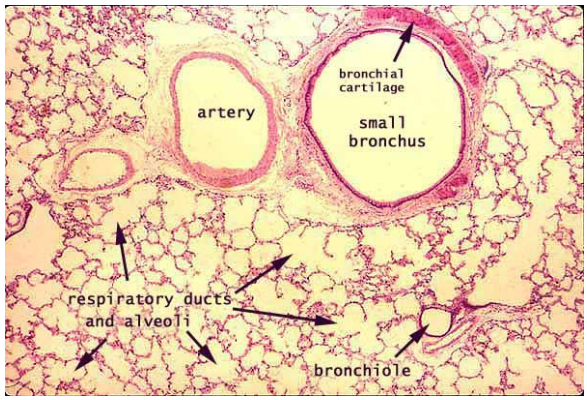

Similarly, you will probably not be able to identify the **capillaries** within the alveolar walls because they collapse as the tissue is being prepared for sectioning. However, you should understand that numerous capillaries were present during life, as diagramed in Figure 22.12 of your Saladin text.

Scan around your slide under low power and you should be able to identify one or two **bronchioles**. These appear as larger spaces lined by a low cuboidal epithelium with a small amount of loose connective tissue in the wall, and often show alveoli branching directly from them. You should also be able to identify **arterioles**, which are lined with a simple squamous epithelium and have connective tissue and/or smooth muscle in their walls. These often also have blood visible within them. **Venules** will collapse during processing and thus will not be easily identified, but you should realize these must also be present in the lung.

Questions for discussion:

What happens to the tissue of the trachea and bronchi when you get "bronchitis"? Why does this make you cough? Why does it make it more difficult for you to breathe?

What happens to the tissue of the lungs in emphysema? Why does this make it more difficult for you to breathe?

RESPIRATORY SYSTEM OF THE CADAVER:

Exercise 8: With the cadaver supine (face up), identify the **trachea** in the thorax. The cartilage rings in its wall are easily felt. Identify the **primary bronchi** which branch from it and follow these to the **lungs,** noting that the cartilage rings continue.

With your fingers, you can also feel the pulmonary arteries (thicker walls) and pulmonary veins (thinner walls) entering the **hilum** of each lung. Encircle these structures at the hilum with your thumb and index finger - you should be able to get their tips fairly close together, demonstrating the small area through which structures entering and leaving the lung must pass.

Place your hands into the **pleural cavities** - they can pass completely behind the lungs. You can feel the ribs and intercostal muscles through the parietal pleura against the dorsal surfaces of the hands and fingers. Lift the lungs gently to demonstrate that they are connected to other structures only at their hilums.

On the right lung, identify the **superior lobe**, **middle lobe**, and **inferior lobe**. On the right lung, identify the **superior lobe** and **inferior lobe**. Confirm that the inferior lobe of each lung is primarily located posterior to the other lobes.

RESPIRATORY ORGANS IN THE LIVING HUMAN:

Exercise 9: On yourself or another person, identify the location of the **nasal cavity, oral cavity, pharynx, larynx, trachea,** and **lungs**. This will require the removal of clothing so you will probably want to do this at home. Use a pen (preferably water soluble) to draw these structures on the skin. Palpate (that means feel with your fingers) your “Adam’s apple”, which is the thyroid cartilage of the larynx. Inferior to this you can feel the cartilage rings of your trachea. Continue to palpate your thyroid cartilage while you swallow two or three times - you will feel it move up and down each time. Notice that you can breathe while the larynx is in the lower position but you can not breath while it is up - this is because the epiglottis has been pulled down to cover the opening into the larynx.

Examine your **nostrils** in a mirror - you can see the hairs which surround them to filter out large dust particles. Insert the little finger of one hand through the nostril on that side (don’t worry - it can be washed). You can feel the cartilage which forms the anterior part of the nasal septum medially. Laterally, you can feel the inferior nasal concha, although the space between this and the nasal septum is so narrow that you probably can not get your finger past it.

While watching in a mirror with your thorax exposed (on another person would even be better), take three or four deep breaths. Based on the movement of your thoracic wall you should be able to visualize the movement of the lungs within the cavity, including the need for the visceral and parietal layers of the pleura to slip past each other.